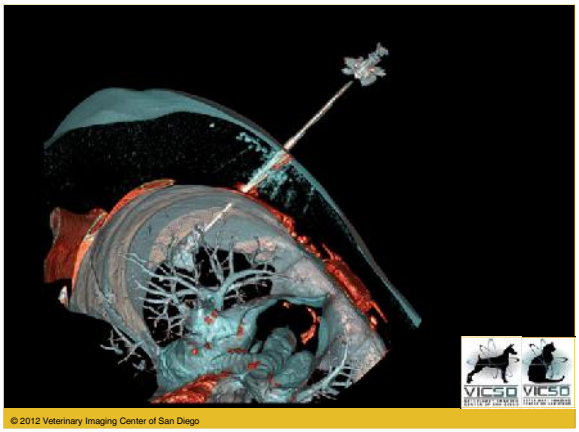



## Ultrasound-Guided Tissue Sampling: Fine Needle Aspirates & Biopsies

**Dr. Marina Ivančić**
Diplomate, American College of Veterinary Radiology
Veterinary Imaging Center of San Diego
08 February 2012



## Ivančić = “Even-Cheech”

≠

Ivan-kick
Ultrasound Lady
"Ultrasound"



## Indications for US-guided tissue sampling

**Diagnostic**

- Ultrasonographic lesion detected & additional info needed
  - Focal
  - Diffuse
- Radiographic lesion amenable to sampling
  - Peripheral
- Neoplastic process that warrants staging
  - US normal/abnormal
- Biochemical abnormality associated with a specific organ
- Cholecystocentesis

**Therapeutic/Diagnostic**

- Pleural, peritoneal, or pericardial effusion
- Pyelocentesis/pyelography
- Cyst drainage
  - Perinephric
- Introduction of pharmaceutical agents



## Tissues to Sample

- Liver
- Spleen
- Kidneys
- Adrenals (if large enough)
- Pancreas
- Bowel mass (if thick enough)
- Lymph nodes
- Prostate
- Lung
- Mediastinal lesions
- Larynx (if mass)
- Thyroid
- Parathyroid
- Bone
- Others I have forgotten

## Contraindications for FNA and/or core biopsy

- Inability to obtain acoustic window: Gas/Mineral
- For Core Biopsy: Thrombocytopenia, ↑PT/PTT
- For either procedure: A patient that can't keep still!
- Be aware that a patient with effusion has an ↑likelihood of hemorrhage



## Benefits of US-guided tissue sampling

- Real-time visualization of needle tip within tissue
- Real-time detection and characterization of blood flow in tissue of interest using color Doppler



## FNA vs. Core Biopsy: Pros and Cons

| Fine Needle Aspirate | Core Biopsy |
|---|---|
| **PRO**<br>• Minimally invasive<br>• Low risk of complications<br>• Cheap<br>• Quick<br>• Sedation or awake | **PRO**<br>• ↑ information relative to FNA<br>• Less invasive than sx<br>• Less expensive than sx |
| **CON**<br>• Limited information relative to bx<br>  ○ Architecture<br>  ○ Fibrosis | **CON**<br>• More invasive & expensive than FNA<br>• Higher risk of complications than FNA<br>• Need GA |

US helpful here!

## Patient preparation: FNA

- Fasted
- Calm
- Motionless
  - Infer what you will



"Megan" Shumka

## Patient preparation: Core biopsy

- Fasted
- General anesthesia
  - Propofol or inhalant gas
- BEFOREHAND…
  Evaluate
  - Platelet count
  - PT/PTT (Prothrombin Time, Partial Thromboplastin Time)



## PT/PTT

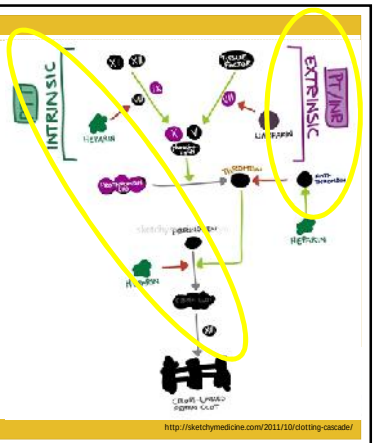




http://sketchymedicine.com/2011/10/clotting-cascade/

## Thromboelastography (TEG)

- Tests **efficiency** of coagulation
- **Only** test that assesses clot initiation, amplification, propagation, & fibrinolysis
- Evaluates both **cellular** & **plasma** components of coag

http://www.aacc.org/publications/cln/2010/december/Pages/Thromboelastography.aspx#

## FNA: Procedure Overview

- 22g is the perfect size
  - Smaller = low cellularity
  - Larger = more hemodilution
- 1.5" needle
  - Occasionally spinal needle
- Skin prep
  - Scrub, alcohol
- Slides available
- Pass needle through tissue
- To aspirate or not to aspirate?
- Speed



## FNA: Procedure Overview


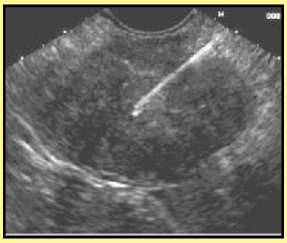

http://roundlydismissed.blogspot.com/ http://www.jgh.org/Past-Issues/Volume-5---Issue-2/Endoscopic-Ultrasound-of-the-Gastrointestinal-Trac.aspx

## Core biopsy: Procedure Overview

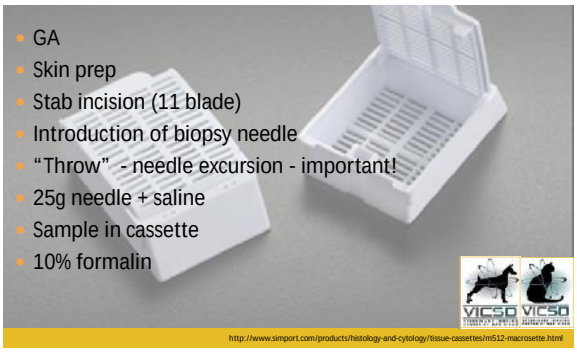

- GA
- Skin prep
- Stab incision (11 blade)
- Introduction of biopsy needle
- "Throw" - needle excursion - important!
- 25g needle + saline
- Sample in cassette
- 10% formalin

http://www.simport.com/products/histology-and-cytology/tissue-cassettes/m512-macrosette.html

## Core biopsy: Procedure Overview

Proot JVIM 2006: 19% (5/26) cats with liver bx using automated device developed fatal vagotonia associated with pressure wave



http://www.alibaba.com/product-gs/248515542/Biopsy_Needles_Biopsy_System_.html

http://www.haomed.com/site/chuanci/English/

## Sampling Intrathoracic Lesions


- PERIPHERAL ONLY!
- Pleural effusion helps
- Limitation: Aerated lung

- FNA 91% diagnostic, 0% complications

(Reichle 2000)

## Sampling Intrathoracic Lesions

- CT-guided
  - Relatively safe and useful
  - Esp with neoplasia
  - Subclinical pneumo & hemorrhage common when aerated lung penetrated
    (Zekas Vet Radiol 2005)



## Sampling Osseous Lesions

- FNA
  - 75-98% diagnostic!
  - May obviate need for bx
    (Samii Vet Radiol 1999)
- Core biopsy
  - Sample entire thickness of bone
  - 100% diagnostic in recent CT study
    (Vignoli JAVMA 2004)
- US or CT-guided

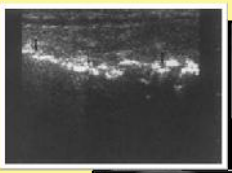

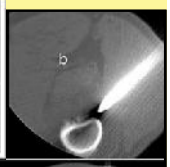


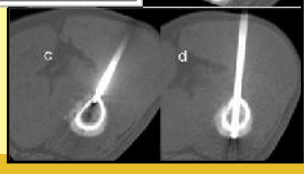




## A few of the papers I read for this talk

## Literature Take-Home Messages

- Complications rates for core biopsies:
  - Insignificant
    - 5.6-21.9%
  - Significant
    - 1.2-6%
- FNA vs. Core Biopsy
  - Small lesions
  - Cystic lesions
  - Vascular lesions
- Tumor type & sample success
  - Round cell tumors > mesenchymal tumors

Vignoli, Saunders. 2011. Image-guided interventional procedures in the dog and cat. Vet J 187:297-303.

## Literature Take-Home Messages

- Liver
  - Hepatic FNA is highly sensitive for suppurative & chronic active inflammation, but not for lymphocytic hepatitis (Weiss 2001)
  - Agreement b/t cyto and histo: 30.3% - 51.2% (Wang 2004)
  - Cyto from FNA and architecture info from US work in tandem
- Spleen
  - Cyto/Histo correlation: 61% (Ballegeer 2007)
  - FNA and core biopsy can be done *safely* (Watson 2011)
    - Adding bx to FNA provides complementary info
  - Sampling cavitary masses typically non-diagnostic



## Literature Take-Home Messages

- Kidneys
  - FNA often to rule-in/out lymphoma
  - Core biopsy to definitively diagnose renal pathology
  - Complications: 13.4% dogs, 18.5% cats (Vaden 2005)
- Pancreas
  - Can be sampled safely (Mueller 1988, Nyland 2002)
  - Avoid passing through normal tissue to ↓ risk of pancreatitis
- Urinary Bladder
  - Seeding reported with transabdominal FNA
  - Recommend US-guided catheter placement & targeted negative pressure
- Adrenal Glands
  - Sampling can be performed if large
  - Avoid if pheochromocytoma suspected - - hyper/hypotensive crisis

## Fun with Ultrasound!

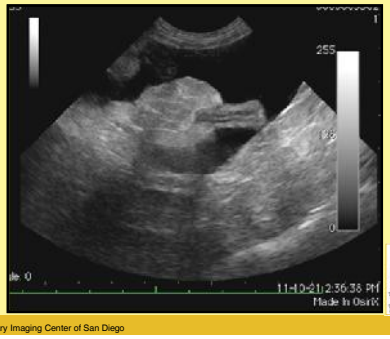




## Literature Take-Home Messages

- Prostate
  - Can be sampled safely
  - Avoid urethra and sublumbar/inguinal vessels
  - Strong correlation (75% agreement) between cyto & histo for prostatic dz (Powe Vet Clin Path 2004)
- Lymph nodes
  - Very good correlation between cyto and histo in dogs (DeSwarte Vet Radiol 2011)
- Laryngeal masses
  - UF of laryngeal masses allows F NA with ↓ ↓ risk of hemorrhage, edema that would further ↓ lumen (Rudorf, Vet Radiol 1998)



## Literature Take-Home Messages: MCT

- Dogs with MCT in liver and spleen have *significantly* shorter survival times
- Alteration in US appearance of these organs is *not* a reliable predictor of MC infiltration
- **Routine US-guided FNA of liver and spleen should be performed in *all* canine MCT patients at risk for metastasis *regardless* of US appearance**

Book Vet Radiol 2011
Stefanello JVIM 2009

## Literature Take-Home Messages: MH

- Malignant histiocytosis often causes hypoechoic nodules in liver, spleen, etc.
- However, US appearance of canine abdominal malignant histiocytosis is **non-specific**
- **Cytology or histopathology is needed for dx**

Ramirez Vet Radiol 2002



Crabtree et al, Vet Radiol 2010

## Literature Take-Home Messages: Lymphoma

- FNA of spleen and liver in 28 dogs with confirmed lymphoma
- FNA 82-86% diagnostic
- **FNA is recommended for detection of lymphoma in the <u>spleen</u> of dogs if the spleen is ultrasonographically <u>ab</u>normal**
- **FNA is recommended for detection of lymphoma in the <u>liver</u> of dogs <u>regardless</u> of its ultrasonographic appearance**



Crabtree et al, Vet Radiol 2010

## Fun with Ultrasound!

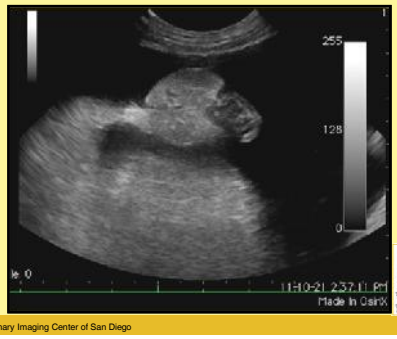

## On the horizon? Endoscopic Ultrasound

- Indications
  - Intrathoracic soft tissue lesions
  - Space-occupying lesions difficult to evaluate with AUS due to gas
  - Gaschen Vet Radiol 2003

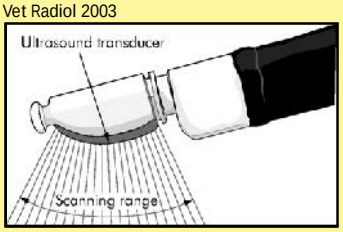




http://thorax.bmj.com/content/61/9/795.abstract

## Endoscopic Ultrasound

Abdomen
- Both pancreatic lobes
- Liver
- Lymph nodes
- Gastric wall
- Duodenum
- Colon

Other
- Intrapelvic
- Obese patients

Thorax
- Mediastinum
- Tracheobronchial LNs
- Esophagus
- Pulmonary lesions



http://thorax.bmj.com/content/61/9/795.abstract

## CT-guided tissue sampling

Useful whenever mineral or gas preclude US

- Peripheral thoracic lesions
- Osseous lesions

## Speaking of CT (and MRI)…

- Food for thought:
- Why not image patients at an institution where "everything could be done all at once" - ?
- Two important reasons:



## Dispelling Myths

- "They can rush right into surgery following the scan"



## Dispelling Myths

- **MOST OF THE TIME, THIS IS NOT WHAT YOU WANT**
  - Can be hundreds, sometimes thousands of images to evaluate
  - *Assuming patient is stable*,
    - Want someone to pore over the images
    - Want someone to consult with fellow radiologists
- Hence:

VICSD VETERINARY IMAGING CENTER OF SAN DIEGO

## Point Two

- Currently conducting cross-sectional imaging off-site
- No one else in San Diego county is using:

  **64** slice CT

  **1.5 Tesla** MRI
- What does that mean?

  **Speed**

  **Image Quality**



## Questions?